



# Syndrome d'électrocoagulation postpolypectomie (*SCPP*)

Dr Christian Blais

Dre Émilie Comeau

Dr Vincent Michaud (R3)

**Octobre 2017 CHUS**

# Plan



1. Cas clinique
2. Survol théorique SCPP
3. Revue littérature radiologique
4. Exemple
5. Traitement

# CAS



64 ans

## Symptômes:

- Dlr abdo depuis 3 jours
- T°=38°C
- Nausées / Vomissement
- Selles molles

## E\P:

- SV stables
- Dlr palpation FID
- Ressaut équivoque





# CAS

## **Bilan:**

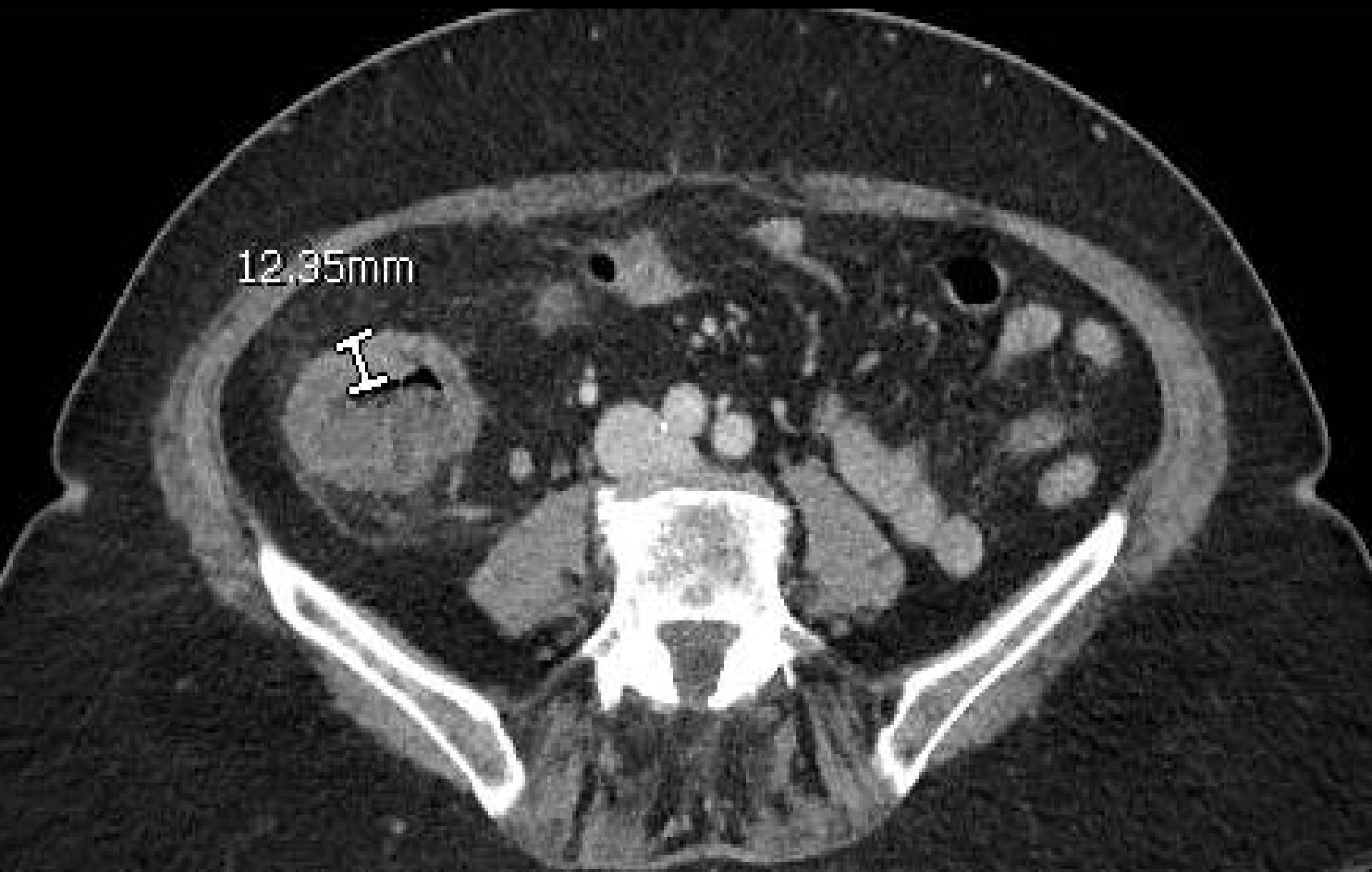- CRP = 119 mg/L
- FSC N
- Lactate N

## **Coloscopie dépistage x 3 jours:**

- Polypectomie au caecum
- Anse diathermique (« Snare »)

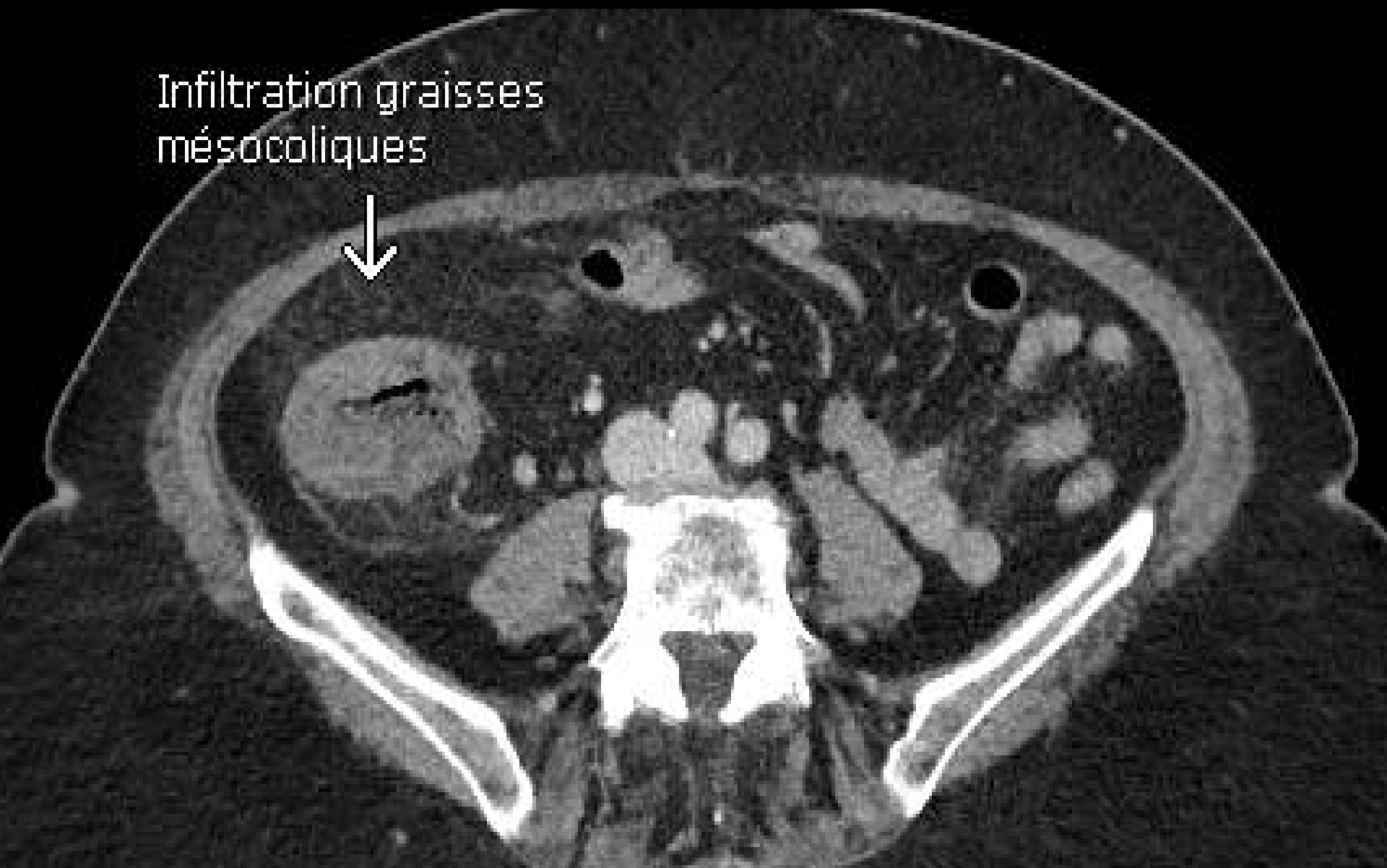CAS

12.35mm



CAS

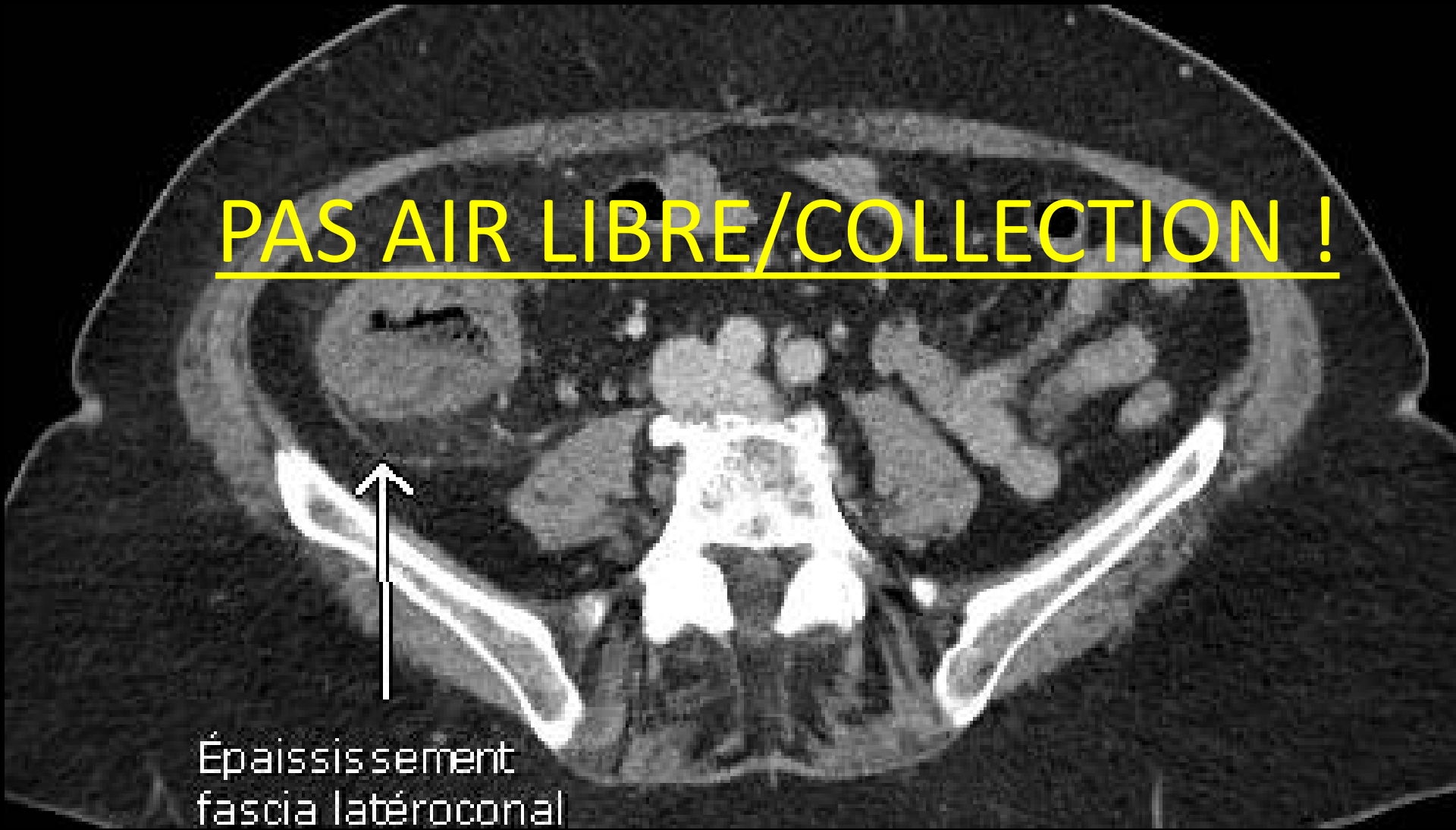
Infiltration graisses  
mésocoliques



CAS

PAS AIR LIBRE/COLLECTION !

↑  
Épaississement  
fascia latéroconal





Diagnostic?

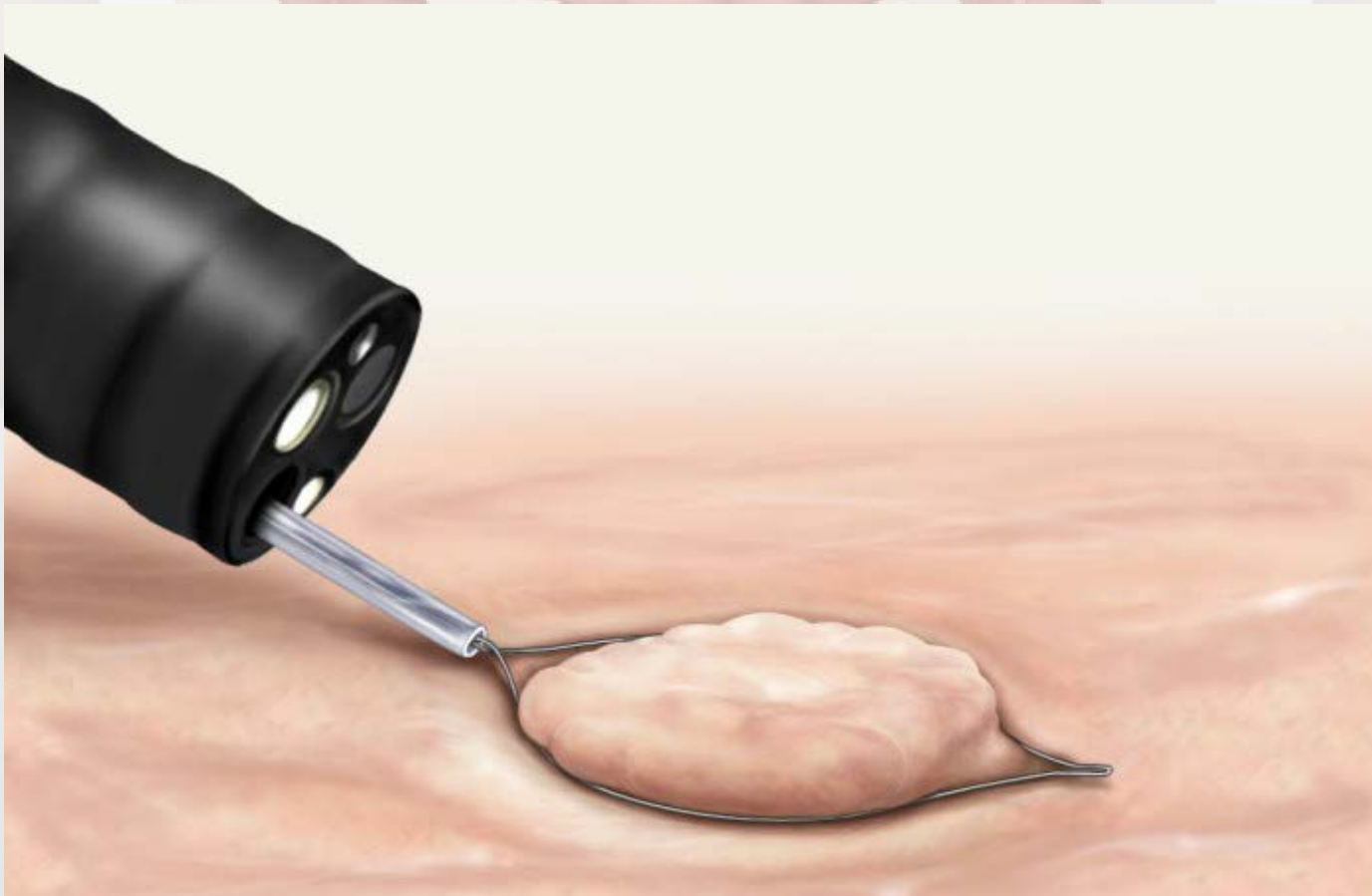
**Syndrôme d'électrocoagulation  
postpolypectomie**

*DDX: Perforation (très peu probable)*



# Le coupable?

Anse d'électrocoagulation (« Snare »)



# Mécanisme SCPP

An anatomical illustration of the human large intestine (colon) within a light-colored torso. The colon is shown in a pinkish-red color with its characteristic haustra. The text is overlaid on the diagram.

Brûlure colique transmurale

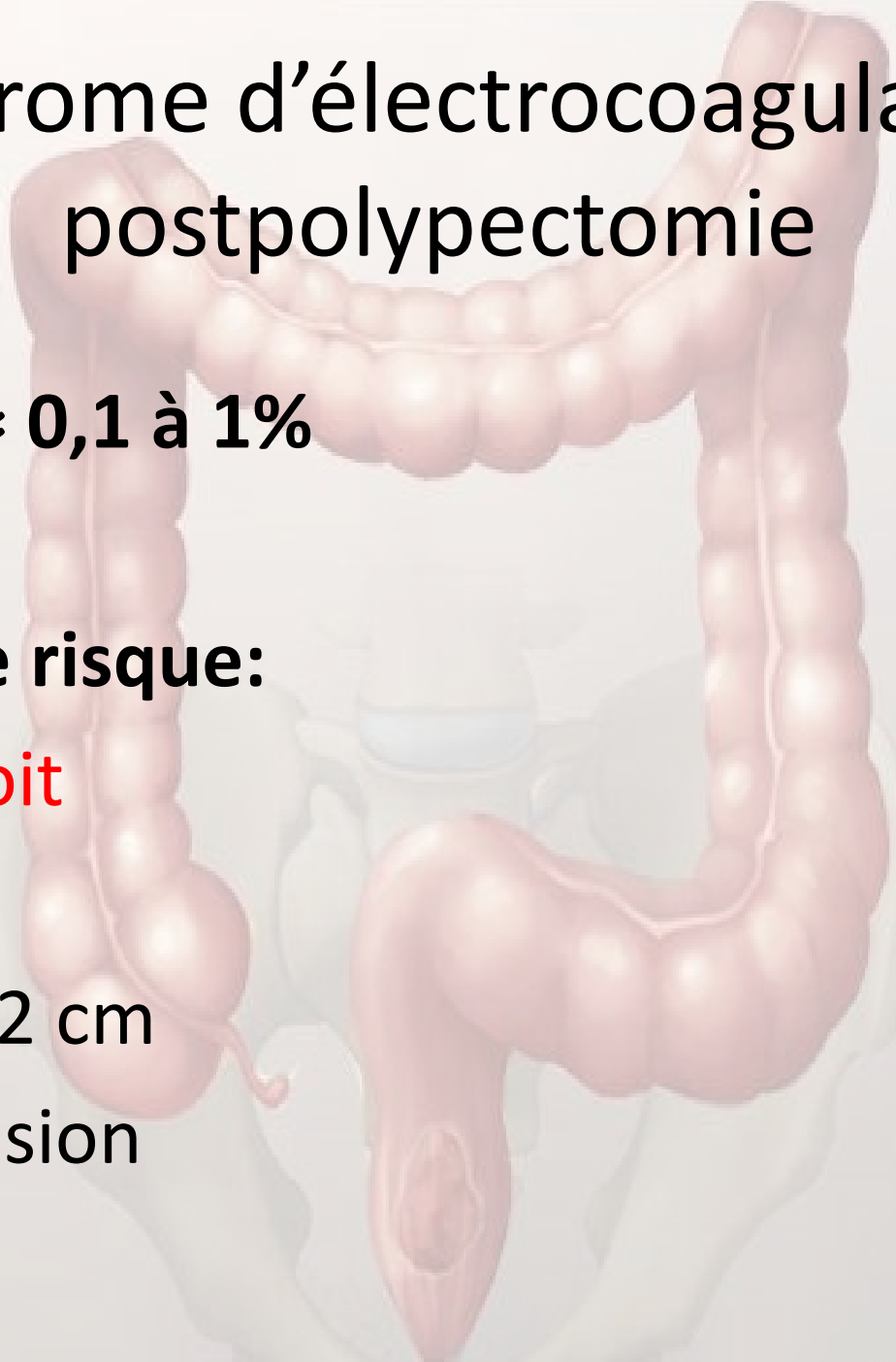
*Sans perforation*

# Syndrome d'électrocoagulation postpolypectomie

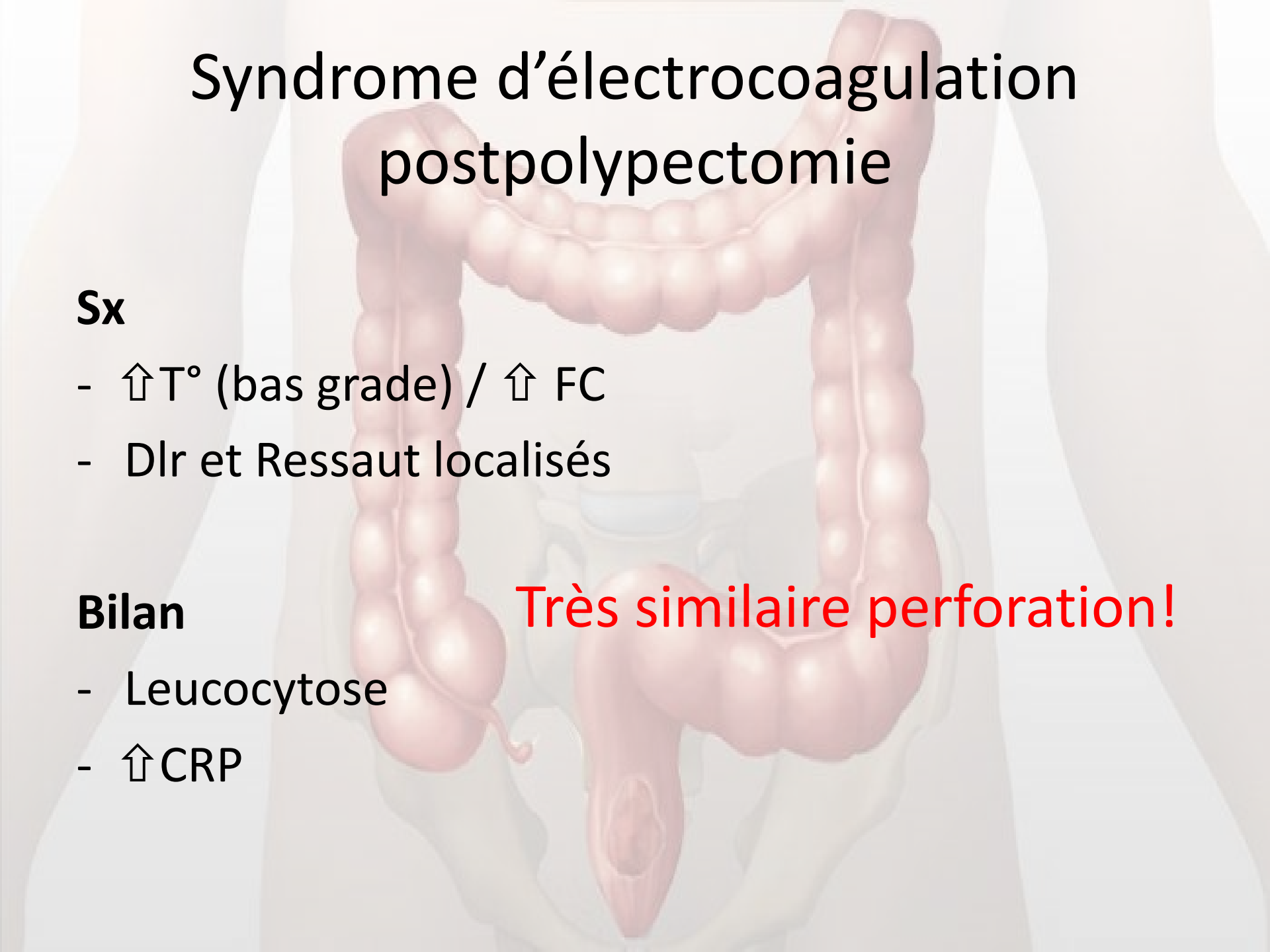
**Incidence  $\approx$  0,1 à 1%**

**Facteurs de risque:**

- **Côlon droit**
- Sessile
- Polype  $>$  2 cm
- Hypertension



# Syndrome d'électrocoagulation postpolypectomie



## Sx

- ↑T° (bas grade) / ↑ FC
- Dlr et Ressaut localisés

## Bilan

- Leucocytose
- ↑CRP

Très similaire perforation!

## CT findings of post-polypectomy coagulation syndrome and colonic perforation in patients who underwent colonoscopic polypectomy

[Y.J. Shin](#), [Y.H. Kim](#)  , [K.H. Lee](#), [Y.J. Lee](#), [J.H. Park](#)

Department of Radiology, Seoul National University Bundang Hospital, Seoul National University College of Medicine, Institute of Radiation Medicine, Seoul National University Medical Research Center, South Korea

**October 2016** Volume 71, Issue 10, Pages 1030–1036



# Objectif de l'étude

Investiguer caractéristiques cliniques et **radiologiques** du SCPP et perforation

# Population

5542 pt Postpolypectomie



8 SCPP / 6 Perforation



5 exclus (*pas tdm*)

=

**4 SCPP / 5 Perforation**

**Table 2**

Computed tomography findings of patients with post-polypectomy

	Postpolypectomy coagulation syndrome		
	Patient 1	Patient 2	Patient 3
Presence of extraluminal air	No	No	No
Location of extraluminal air	NA	NA	NA
Location of an involved colonic segment	Cecum	Ascending colon	Ascending colon
An involved segment			
Pattern	Concentric	Concentric	Concentric
Length (mm)	66	158	240
Thickness (mm)	21	18	17
Pattern of enhancement	Stratified	Stratified	Stratified
Presence of mural defect	Yes, fluid	Yes, fluid	Yes, fluid
Surrounding infiltration	Yes	Yes	Yes
Surrounding fluid collection	No	No	No
Peritoneal or fascial thickening	Yes	Yes	Yes

Note—NA, not applicable.

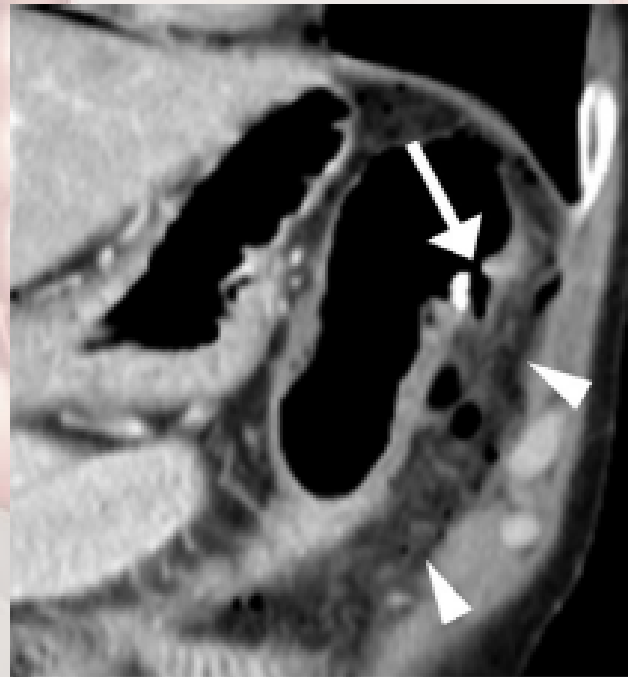
Presence of extraluminal air  
 Location of extraluminal air  
 Location of an involved colonic segment  
 An involved segment  
 Pattern  
 Length (mm)  
 Thickness (mm)  
 Pattern of enhancement  
 Presence of mural defect  
 Surrounding infiltration  
 Surrounding fluid collection  
 Surrounding fluid collection  
 Peritoneal or fascial thickening

	Patient 3	Patient 4	Patient 5
Presence of extraluminal air	Yes	Yes	Yes
Location of extraluminal air	Pneumoperitoneum, pneumoretroperitoneum	Pneumoretroperitoneum	Pneumoperitoneum
Location of an involved colonic segment	Transverse colon	Descending colon	Descending colon
An involved segment			
Pattern	Concentric	Concentric	Concentric
Length (mm)	35	38	28
Thickness (mm)	7.5	7.3	5.6
Pattern of enhancement	Stratified	Stratified	Homogeneous
Presence of mural defect	No	Yes, air	Yes, air
Surrounding infiltration	No	Yes	Yes
Surrounding fluid collection	No	Yes	Yes
Surrounding fluid collection	No	Yes	Yes
Peritoneal or fascial thickening	No	Yes	Yes



# Air libre

	Postpolypectomy coagulation syndrome				Colonic perforation				
	Patient 1	Patient 2	Patient 3	Patient 4	Patient 1	Patient 2	Patient 3	Patient 4	Patient 5
Presence of extraluminal air	No	No	No	No	Yes	Yes	Yes	Yes	Yes

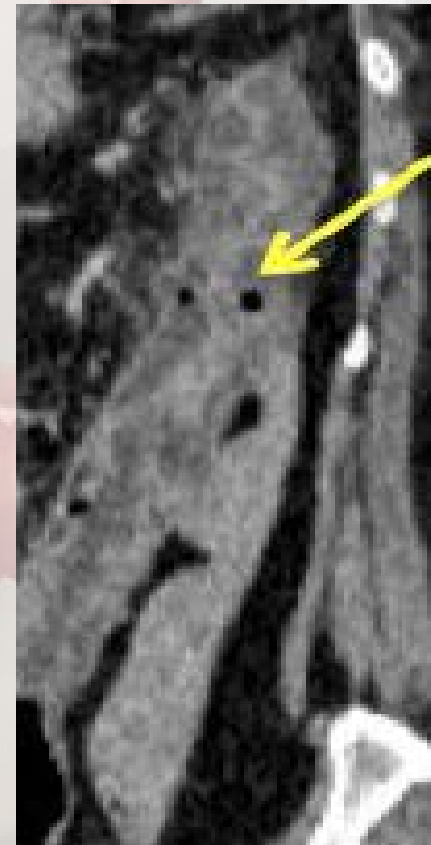

# Epaissement pariétal

	Postpolypectomy coagulation syndrome				Colonic perforation				
	Patient 1	Patient 2	Patient 3	Patient 4	Patient 1	Patient 2	Patient 3	Patient 4	Patient 5
Thickness (mm)	21	18	17	15	6.6	10	7.5	7.3	5.6

Y.J. Shin et al / Clinical Radiology 71 (2016) 1030–1036

*SCPP > Perforation!*



Radiology Case 2013 Sep; 7(9):27-32

## Longueur atteinte

	Postpolypectomy coagulation syndrome				Colonic perforation				
	Patient 1	Patient 2	Patient 3	Patient 4	Patient 1	Patient 2	Patient 3	Patient 4	Patient 5
Length (mm)	66	158	240	145	21	63	35	38	28


Y.J. Shin et al. / Clinical Radiology 71 (2016) 1030–1036

*SCPP > Perforation!*

# Type rehaussement pariétal



En cible



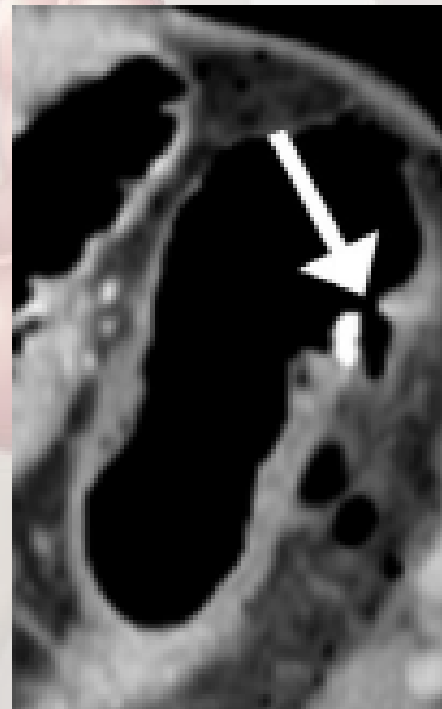
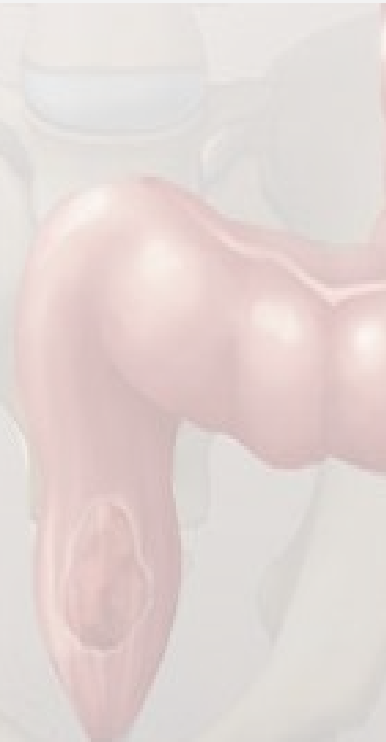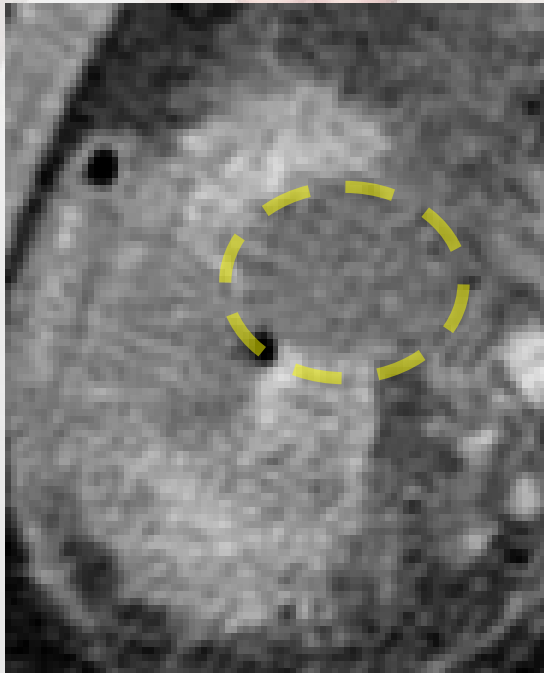
Homogène

	Postpolypectomy coagulation syndrome				Colonic perforation				
	Patient 1	Patient 2	Patient 3	Patient 4	Patient 1	Patient 2	Patient 3	Patient 4	Patient 5
Pattern of enhancement	Stratified	Stratified	Stratified	Stratified	Homogeneous	Homogeneous	Stratified	Stratified	Homogeneous

# Défaut pariétal???

(vs défaut rehaussement)

	Postpolypectomy coagulation syndrome				Colonic perforation				
	Patient 1	Patient 2	Patient 3	Patient 4	Patient 1	Patient 2	Patient 3	Patient 4	Patient 5
Presence of mural defect	Yes, fluid	Yes, fluid	Yes, fluid	Yes, fluid	No	No	No	Yes, air	Yes, air

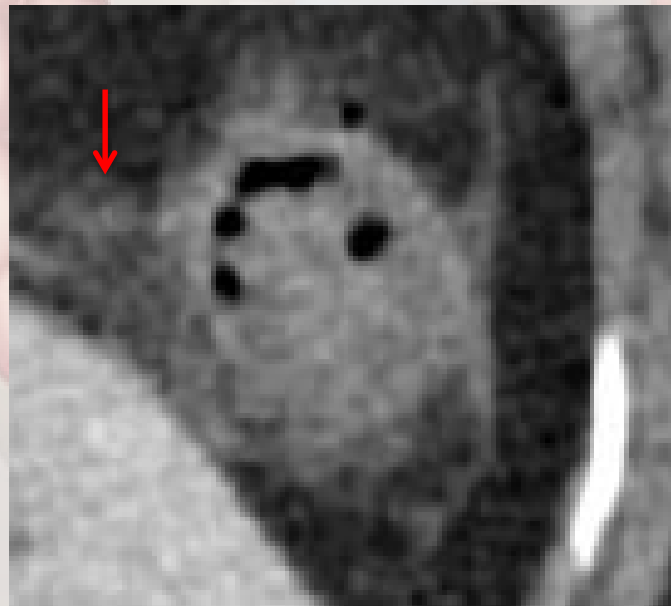


YJ. Shin et al / Clinical Radiology 71 (2016) 1030–1036

# Infiltration graisse mésocolique

	Postpolypectomy coagulation syndrome				Colonic perforation				
	Patient 1	Patient 2	Patient 3	Patient 4	Patient 1	Patient 2	Patient 3	Patient 4	Patient 5
Surrounding infiltration	Yes	Yes	Yes	Yes	No	Yes	No	Yes	Yes

Y.J. Shin et al / *Clinical Radiology* 71 (2016) 1030–1036

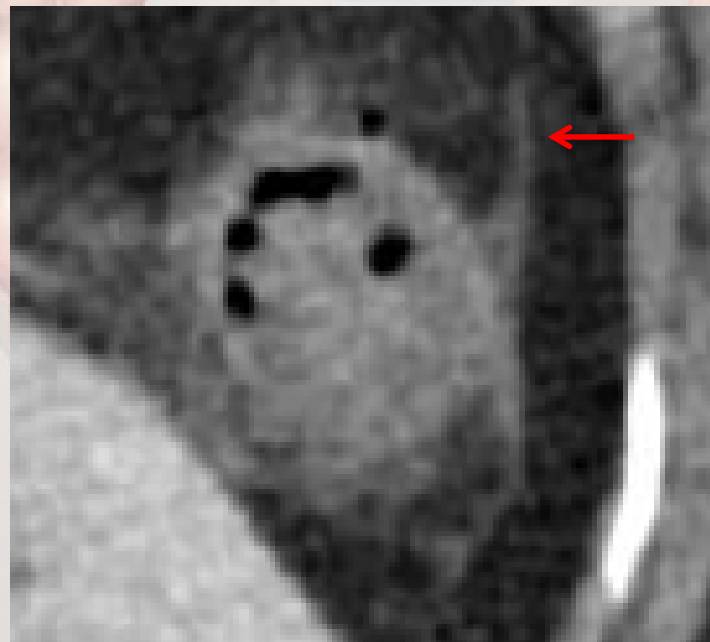


*Radiology Case*. 2013 Sep; 7(9):27-32

# Épaississement fascias/péritoine

	Postpolypectomy coagulation syndrome				Colonic perforation				
	Patient 1	Patient 2	Patient 3	Patient 4	Patient 1	Patient 2	Patient 3	Patient 4	Patient 5
Peritoneal or fascial thickening	Yes	Yes	Yes	Yes	No	Yes	No	Yes	Yes

Y.J. Shin et al / *Clinical Radiology* 71 (2016) 1030–1036



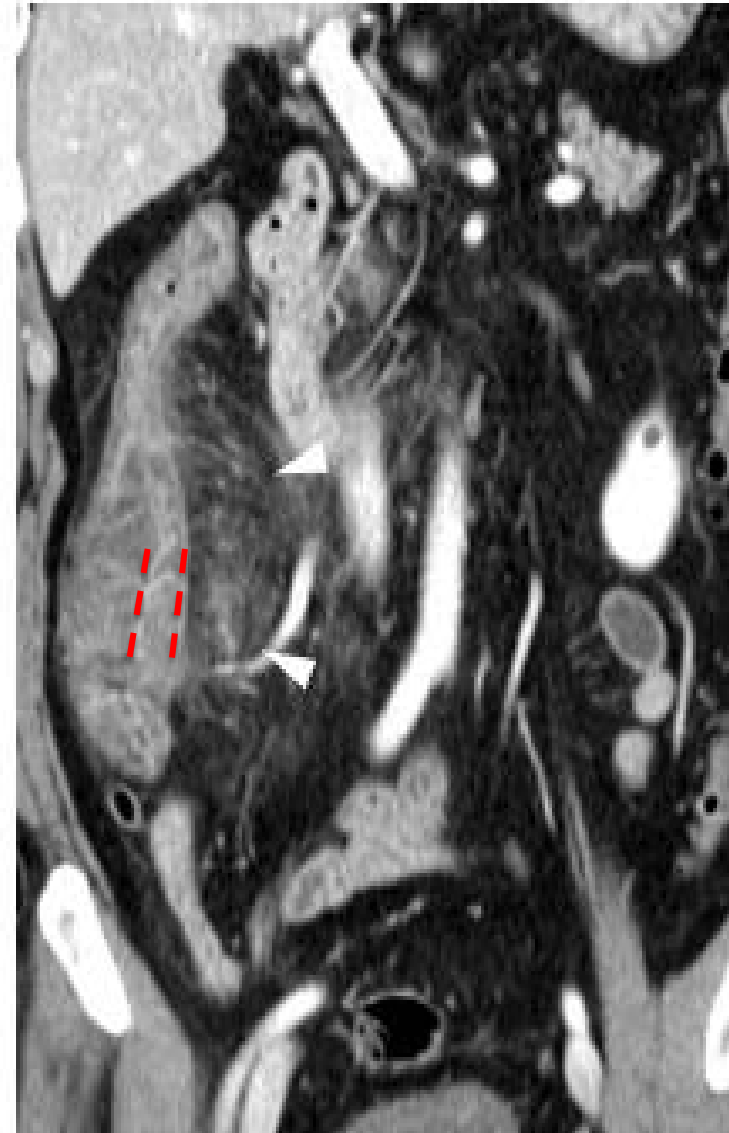
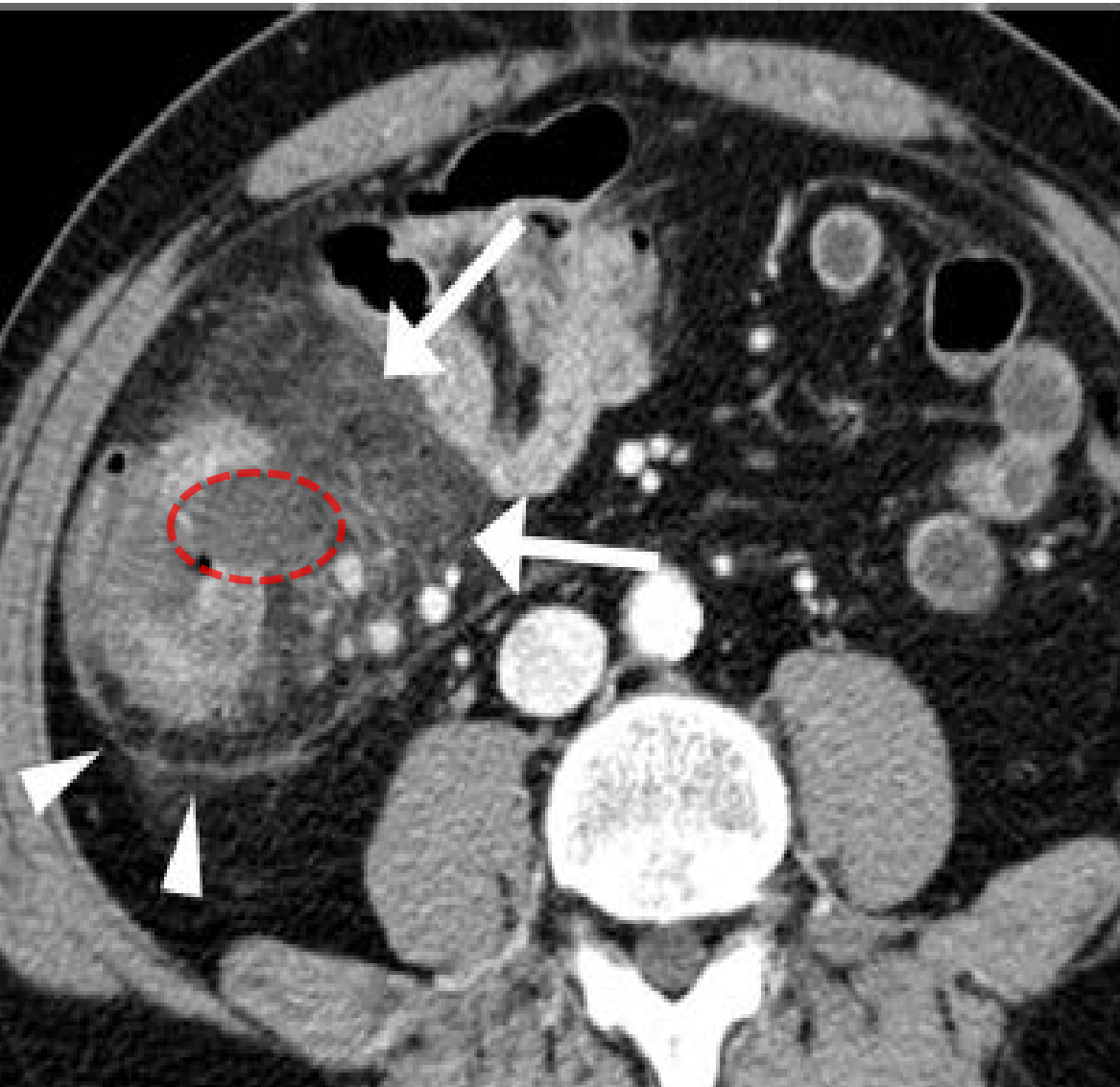
# Trouvailles radiologiques caractéristiques SCPP:

- Épaississement pariétal segmentaire
- Infiltration
- Épaississement des fascias
- ***Défaut de paroi/rehaussement??***
- **Absence air libre!**
- **Absence collection!**



# Example

*Y.J. Shin et al. / Clinical Radiology 71 (2016) 1030–1036*





# Traitement

**CONSERVATEUR!**

*(Si Hospitalisé: hydratation, NPO +- ATB)*

*Tx perforation = SOP*

# Bibliographie

- Articles scientifiques:

- *Clinical outcomes and risk factors of post-polypectomy coagulation syndrome: a multicenter, retrospective, case-control study.* Cha JM, Lim KS, Lee SH, Joo YE, Hong SP, Kim TI, Kim HG, Park DI, Kim SE, Yang DH, Shin JE. *Endoscopy.* 2013;45(3):202-7. doi: 10.1055/s-0032-1326104. Epub 2013 Feb 4.
- *CT findings of post-polypectomy coagulation syndrome and colonic perforation in patients who underwent colonoscopic polypectomy.* Shin YJ, Kim YH, Lee KH, Lee YJ, Park JH. *Clin Radiol.* 2016 Oct;71(10):1030-6. doi: 10.1016/j.crad.2016.03.010. Epub 2016 Apr 13.
- *Radiol Case Rep.* 2013 Sep; 7(9): 27–32. *Imaging findings post colorectal endoscopic mucosal resection.* James A Stephenson, Jonathan Crookdake, Steven Jepson, Peter Wurm, and Mosheir Elabassy.
- *Endoscopy.* 2013;45(3):202-7. doi: 10.1055/s-0032-1326104. Epub 2013 Feb 4. *Clinical outcomes and risk factors of post-polypectomy coagulation syndrome: a multicenter, retrospective, case-control study.* Cha JM1, Lim KS, Lee SH, Joo YE, Hong SP, Kim TI, Kim HG, Park DI, Kim SE, Yang DH, Shin JE.

- WEB:

- [https://www.olympus.co.uk/medical/rmt/media/content/content\\_1/images\\_1/applications\\_3/gastroenterology\\_2/polypectomy/Polypectomy\\_Resection-of-stalked-polyp\\_\\_application\\_001\\_V1\\_20120604~3\\_700x480.jpg](https://www.olympus.co.uk/medical/rmt/media/content/content_1/images_1/applications_3/gastroenterology_2/polypectomy/Polypectomy_Resection-of-stalked-polyp__application_001_V1_20120604~3_700x480.jpg)
- [Radiologyassistant.com](http://radiologyassistant.com)
- <http://leethasworld.fr/douleur-abdominale-vesicule/>



**Merci!**

**Questions?**